

E-MAIL (web)

**\*22541557\***

Request # 22541557

**254557**

MAY 16, 2007

Email (PDF) To: [medlibrary@leememorial.org](mailto:medlibrary@leememorial.org)

Lee Memorial Health System

Thomas R. Connelly Medical Library

2776 Cleveland Ave.

Fort Myers, FL 33902-2218

**EFTS****DOCLINE: Journal Copy EFTS Participant**

Title: JAMA  
Citation: 1939;112(22):2251-2255  
Article: Perforating ulcers of feet with osseous atrophy..  
Author: Tocantins, LMH & Reimann, HA  
NLM Unique ID: Verify: Manual  
Publisher:  
Copyright: Copyright Compliance Guidelines  
Authorization: Narges Ahmadi  
Need By: MAY 30, 2007  
Maximum Cost: **\$12.00**  
Patron Name: Burns, Ellen, RN  
Referral Reason: Lacking  
Library Groups: ESEA,SEND,TABAMLN,FreeShare  
Phone: 1.239.334-5410  
Fax: 1.239.332-6422  
Comments: **SEND 2B & FreeShare, We Prefer PDF Accept Fax & Mail. Bill through EFTS (forward to [ellen.burns@leememorial.org](mailto:ellen.burns@leememorial.org) or call 334-5868)**  
Routing Reason: Routed to FLUSOF in M/A/N Map Routing - cell 1  
Received: May 16, 2007 ( 11:20 AM EST )  
Lender: University of South Florida/ Tampa/ FL USA (FLUSOF)

This material may be protected by copyright law (TITLE 17,U.S. CODE)

**Bill to: FLUZEI**

Lee Memorial Health System

Thomas R. Connelly Medical Library ILL

2776 Cleveland Ave.

Fort Myers, FL 33902-2218

thorax generally for massive collapse of the lung. The method is easy to carry out and mechanically rational. Since all patients with pulmonary atelectasis show increased negative intrapleural pressure, it seems likely that the cyanosis and dyspnea are due primarily to a displacement of the heart and great vessels and to an acute overdilatation of the unaffected lung. In cases of atelectasis following abdominal operations, presumably resulting from bronchial obstruction, the marked increase of intrapleural negative pressure can serve only to draw the entire obstructing medium more firmly and deeply into the bronchus, thus perpetuating a vicious cycle. Introducing air into the pleural cavity serves to break the cycle, tends to push the mediastinum back to its original position and probably would enhance the expulsion of the obstructing medium (see Habliston's

## PERFORATING ULCERS OF FEET, WITH OSSEOUS ATROPHY

IN A FAMILY WITH OTHER EVIDENCES OF DYSGENESIS (HARELIP, CLEFT PALATE): AN INSTANCE OF PROBABLE MYELODYSPLASIA

LEANDRO M. TOCANTINS, M.D.

AND

HOBART A. REIMANN, M.D.

PHILADELPHIA

An arresting example of the influence of heredity in disease is the development of the same chronic pathologic process in two or more members of a family when they reach a specified age. The family in the two cases herein reported furnishes such an example.

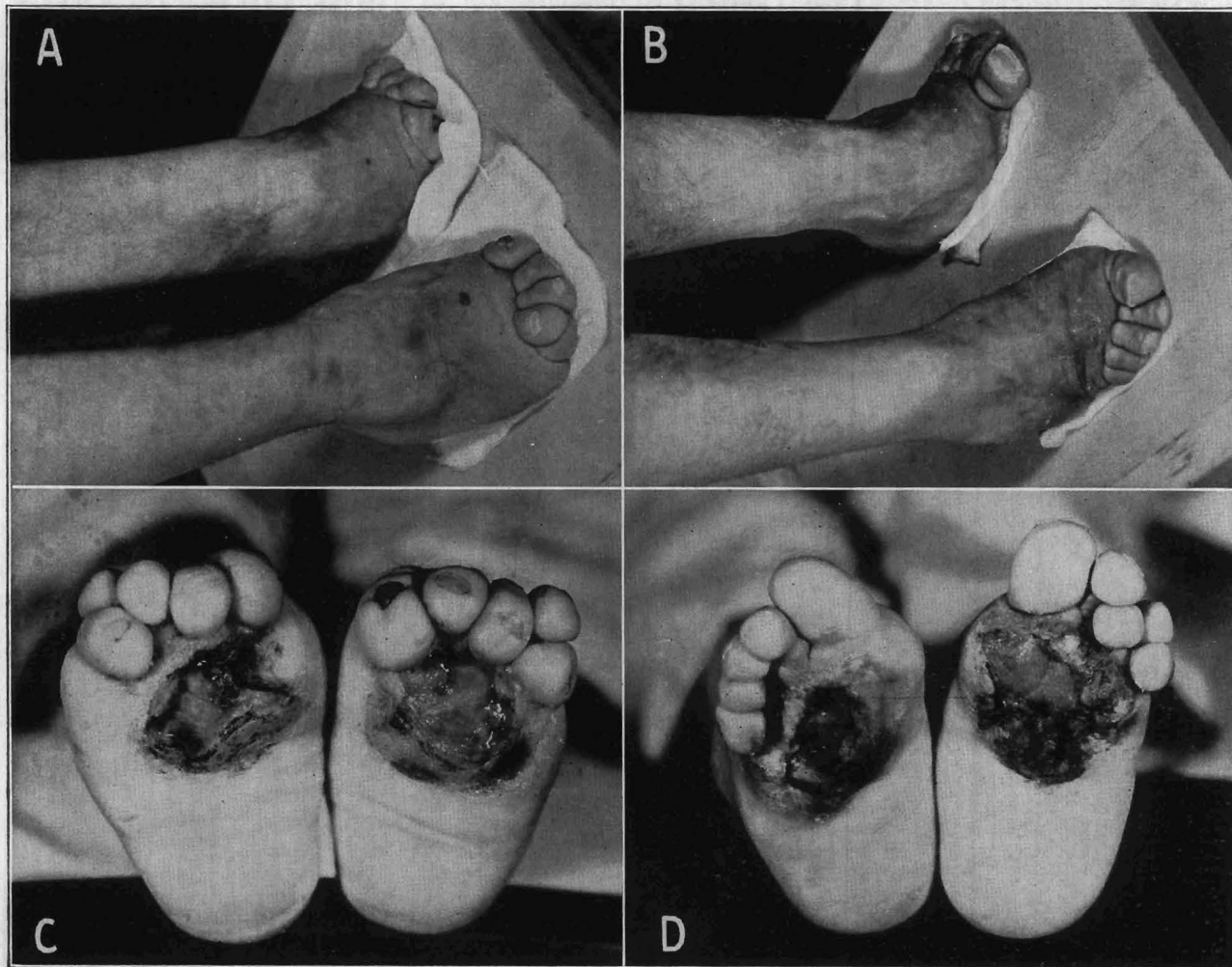


Fig. 1.—A and C, lateral and plantar aspects of the lower extremities of R. D.; B and D, similar aspects of the lower extremities of H. D.

case of intrabronchial tumor expectorated on the second day following artificial pneumothorax).<sup>10</sup>

**Mistakes.**—An investigator who draws false conclusions early in his research may see the whole structure of the work topple, for here conclusions follow in sequence and an early fallacy affects all; moreover, his work is placed on record and is submitted to close and critical supervision. To a physician, mistakes, if not too frequent, are of little consequence—they are indeed inevitable; they do not shake self-confidence as they do in the case of the research worker.—Lewis, Sir Thomas: *Research in Medicine and Other Addresses*, London, H. K. Lewis & Co., Ltd., 1939.

In October 1937 Dr. J. Torrance Rugh of the department of orthopedics received a letter from two young men claiming that they “were very interesting cases” and would like to be studied and treated at this hospital. Through the courtesy of Dr. Rugh the patients, once admitted, were transferred to the medical service, where the following studies were conducted. Only the two principal cases will be dwelt on at length and simple mention made of relevant points in the histories of other members of the family.

Aided by a grant from the J. Ewing Mears Research Fund.  
From the Department of Medicine, Jefferson Medical College and Hospital.

## REPORT OF CASES

**CASE 1.—History.**—H. D., a white man, single, aged 27 (D-17 on the pedigree chart), with no occupation, at the age of 18 noticed a small blister which had appeared on the sole of the right foot followed within two weeks by one on the sole of the left foot. The blister broke down, an ulcer formed and enlarged and a piece of bone was extruded about a month after the onset. He wore at this time a size 5½ shoe. He could then distinguish between heat and cold on the skin of the feet but, as the process spread, sensation for pain, heat and cold disappeared; if he persisted in walking while sequestrums were extruding he felt some discomfort. The loss of sequestrums continued at about the rate of two bony spicules a month. The feet began to shorten and become rigid and apparently fixed at the ankle. At present if he does not use his feet for several weeks the ulcers eventually become smaller and heal over the entire surface; walking about for a few days, however, is

over both knees and on the soles is loose and wrinkled, more markedly on the left side. Both dorsalis pedis arteries are easily palpated, the pulse being full and forcible and apparently equal on the two sides. There are no muscular atrophies or contractures and the muscular strength is normal. There is hypesthesia to touch reaching almost anesthesia over the five toes bilaterally. Sensation of pinprick is almost lost over the feet and is felt more and more up toward the thighs, where it is still slightly impaired. Temperature sense (heat and cold) begins to be impaired just distal to both knees and is completely lost distally to the middle of both legs. Vibratory sense is intact, but the sense of position of the toes is lost. The corneal, laryngeal and pharyngeal reflexes are equal and active. The deep reflexes are equal and hyperactive (+4). The abdominal, cremasteric and achilles tendon reflexes are absent. There are no demonstrable pathologic reflexes or ankle clonus. Oscillometric readings are normal in both thighs and legs;

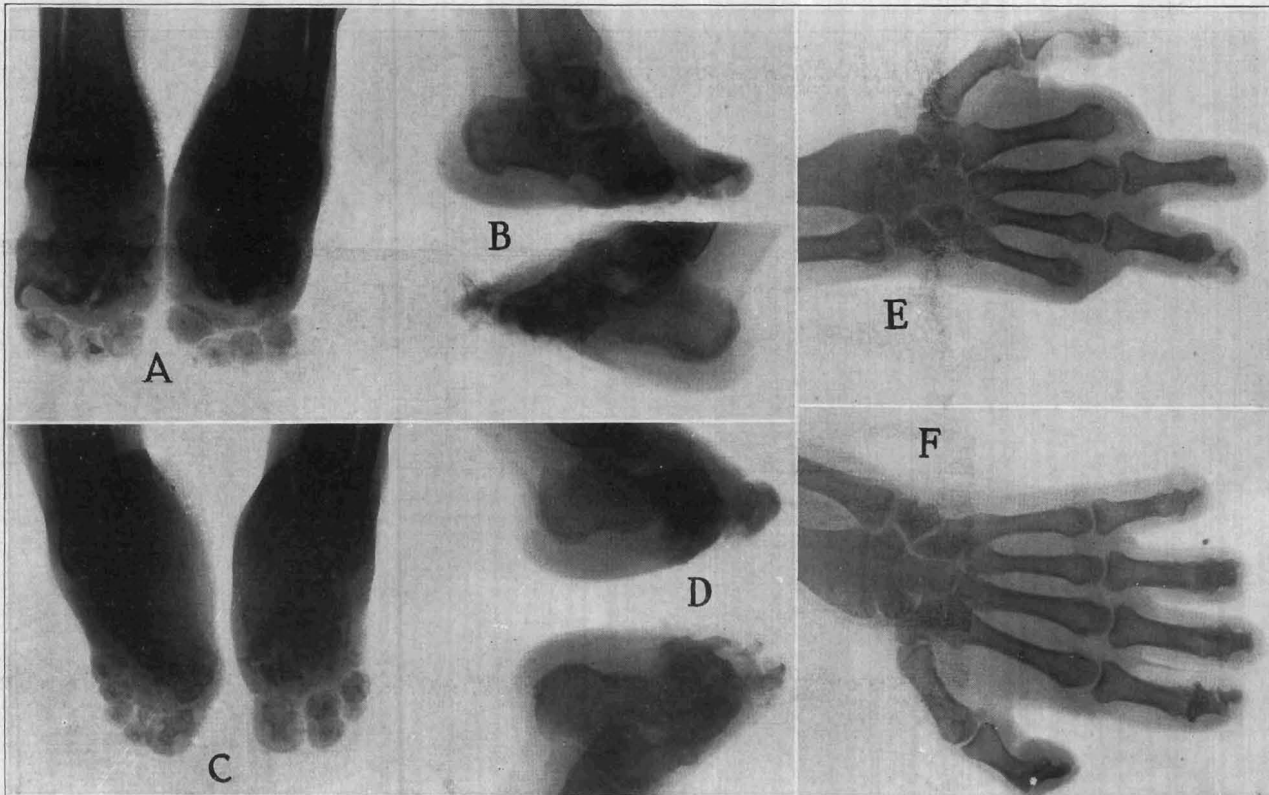


Fig. 2.—Appearances of feet of R. D. (A and B) and of H. D. (C and D) and of the right and left hand (E and F) of A. D., the father of the two boys.

enough to start the ulcerative process over again. The skin of the feet perspires excessively. His general health has been excellent and outside of this disability he has no other complaints. For a time he did amateur boxing, but the necessity of resting every few weeks to allow the ulcers to heal has restricted his activity considerably.

**Examination.**—The patient is an intelligent person with good general muscular development. In the mouth there is an over-riding canine tooth on the left upper maxilla. Examination of the chest and abdomen is negative. There is slight cyanosis of the finger tips. Arm and forearm reflexes are prompt and active and sensation is normal. Distal to both knees there is a dusky pink, patchy discoloration and scaliness of the skin. The lower third of both legs, as well as both feet, are covered with fine perspiration. Both feet are short, in the anterior half especially, the toes appearing to spring directly from the middle portion of the foot without the intervening metatarsals (fig. 1 B). This gives the foot the appearance of a horse's foot ("pferd fuss" of Bruns). About the base of the first toe, the skin is folded over the invaginated toe. On the sole of each foot there is a punched out ulcer with a moist granulating base and sharply limited margins measuring 5 by 2 cm. on the right foot and 6 by 3 cm. on the left (fig. 1 D). The skin

in the feet they are above normal. The temperature, pulse and respiratory rates are normal. The basal metabolic rate is +11; urinalysis is negative; a blood count revealed 87 per cent hemoglobin, 4,810,000 erythrocytes and 11,900 leukocytes, with a normal differential count. Wassermann and Kahn reactions of the blood are negative. The blood sugar is 75 mg. per hundred cubic centimeters of blood, nonprotein nitrogen 24.4 mg., calcium 11.2 mg., phosphorus 3.7 mg. and phosphatase 3.8 mg.

Roentgenologic examination<sup>1</sup> revealed a spina bifida occulta involving the upper segment of the sacrum. When iodized oil was injected into the spinal canal, no obstruction to the flow of oil or any other abnormality was demonstrated. The bones of the skull have a normal appearance and so have the paranasal sinuses, clavicles, scapulas, ribs, lungs and the lumbar vertebrae, the bones of the pelvis, the radiuses, ulnas, carpals and all the phalanges of the fingers. The sella turcica is a little flattened.

The pelvis and calices of both kidneys as visualized by injection of a radiopaque substance are normal. Metatarsals and

1. The roentgenologic examinations were conducted under the direction of Dr. John Farrell. A neurologic examination of three of the patients was performed by Dr. J. C. McNerney.



phalanges are very much deformed and largely destroyed (fig. 2 C and D). The fibulas show a little roughening and thickening along their margins.

**CASE 2.—History.**—R. D., a man aged 24, single (D-18 on the pedigree chart), brother of patient 1, at the age of 17 noticed a small blister on the sole of his foot (he is uncertain which foot). It was soon followed by a blister on the other foot, ulceration and extrusion of sequestrums. The rest of the history is essentially the same as that of his brother.

**Examination.**—This patient is slightly thinner than his brother but of fairly good general development. There are no significant abnormalities in the head, neck, chest and abdomen except for a soft systolic murmur at the apical area of the heart. There is cyanosis and curving down of all finger nails and slight clubbing of the fingers. The skin of the lower third of the legs and feet has a dusky hue and is scaly and covered with beads of perspiration in the dorsum of the foot. The legs and feet (fig. 1 A and C) have, as a whole, an appearance almost identical with those of his brother. The plantar ulcer on the right foot measures 3.5 by 3.5 cm., while that on the left measures 5 by 5 cm. The dorsalis pedis pulses are full and bounding on both sides. There are no muscular atrophies or contractures, and the muscular strength is normal. Sensation to touch is lost over all the toes and is impaired up to a level just above the knees. There is hypesthesia to pinprick from a level about the union of the upper and middle thirds of the thighs distally, ending with almost anesthesia over the toes. There is complete loss of temperature sense over the distal two thirds of the leg and the entire foot. The vibratory sense, bone, position and deep muscle sense are intact. All reflexes are present except the achilles tendon reflex. The deep reflexes are all hyperactive. No reaction of degeneration is present in the muscles of the legs or feet. The temperature, pulse and respiratory rates are normal. The blood pressure is 120 systolic, 68 diastolic. Oscillometric readings are normal for both lower extremities. The basal metabolic rate is +10. The blood count is 78 per cent hemoglobin, 4,500,000 erythrocytes and 8,900 leukocytes, with a normal differential count. The Wassermann and Kahn reactions of the blood are negative. The blood sugar is 79 mg., nonprotein nitrogen 25 mg., calcium 11.5 mg., phosphorus 4.1 mg. and phosphatase 5.2 units. Urinalysis is negative.

Roentgen examination shows normal bones of the skull, the pelvis, hands, femurs, radiuses, ulnas, paranasal sinuses and thoracic and lumbar vertebrae. The sella turcica is a little smaller than usual. The metatarsals are much deformed and largely destroyed and there are only remnants of the phalanges (fig. 2 A and B). The fibulas show a little roughening and thickening along their margins as though there were some periosteal involvement. An intravenous urogram and the injection of iodized oil in the spinal canal yielded negative results. There was no evidence of spina bifida.

There is only one more brother in a family of twelve children; T. D., aged 22 (D-19), leads an active life and has no complaints except that his feet get cold easily during the winter. There are no physical abnormalities except in the lower extremities; the skin over the inner surface of both legs has scaly patches, and the toes of both feet have a dusky bluish discoloration, most marked in the right third and left great toes. There are five black blister-like areas with a cornified base over the right third toe, plantar surface of the right fifth toe and both first metatarsals, and over the dorsal surface of the fourth left toe. There is a fine perspiration over both great toes. The left foot is colder than the right. Pulsation of the dorsalis pedis artery is full and equal. Light touch is felt over the entire skin surface bilaterally. There is hypesthesia to pinprick starting from about 3 cm. above the ankle distally on both sides, most marked over the first, second and fifth toes. Temperature sense is lost over all the toes. Muscle, bone, vibratory and position senses are intact. Superficial and deep reflexes are present, active

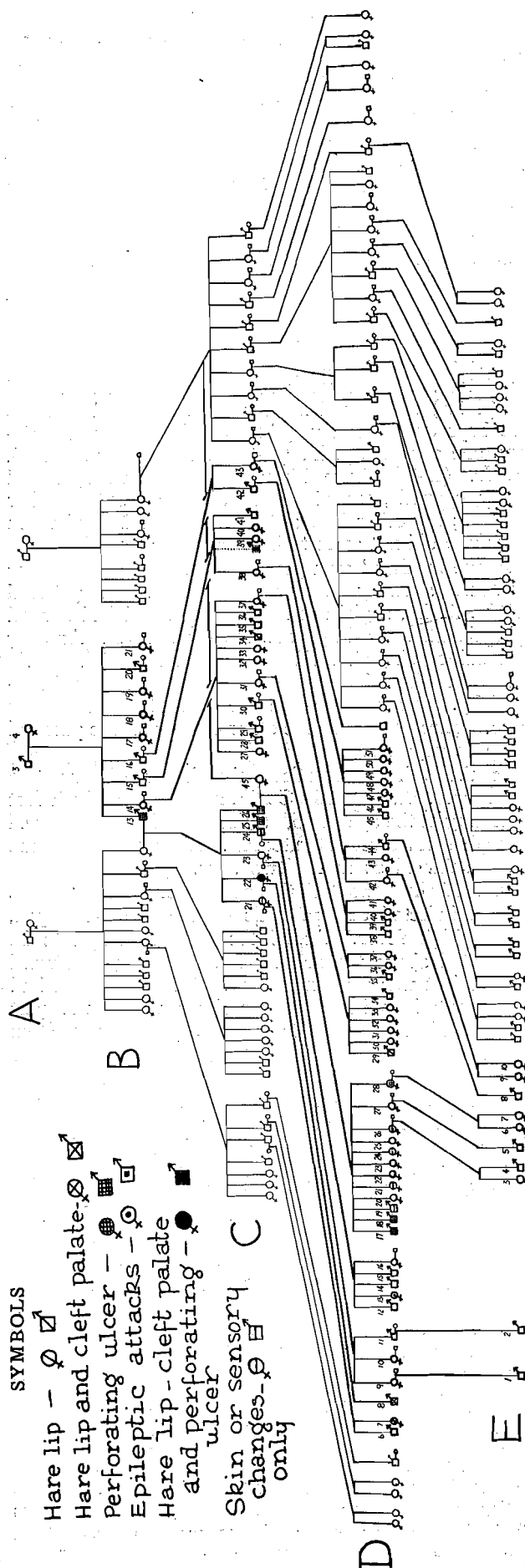


Fig. 3.—Pedigree of the family of H. D. and R. D. (D-17 and D-18). The member indicated by the broken lines between C-38 and C-39 was raised presumably as a son of B-15 but was actually the son of B-13 and therefore is also represented as C-25. As may be readily perceived, the defects are present only in the descendants of A-3 and A-4.

and equal. The deep reflexes are all hyperactive (+ 4). Roentgenologic examination was negative except for the demonstration of a slight bifidity of the spine in the first sacral segment.

Of the nine sisters of these boys only one, E. S. (D-28) was known to have any ulceration of the feet. She died at the age of 25 of heart disease resulting from attacks of rheumatic fever. For six months before her death she had a large ulcer on the plantar surface of her toes similar to those on the feet of the two boys. Another sister, I. D. P., aged 30, married (D-26) had attacks of epileptic-like convulsions with transient loss of consciousness. Neurologic examination yielded negative results except for hyperactive deep reflexes and the presence of a small area of hypesthesia to touch and loss of temperature sense at the tip of the great toes. Of the seven remaining sisters, one, aged 23 (D-27) is in good health; she is married and has two boys one of whom (E-6) has a harelip; two sisters, one aged 15, J. D. (D-21) and another aged 14, M. D. (D-24) have hyperactive deep reflexes and dusky, cyanotic, scaly lower legs and feet but no other changes; the other four sisters are under 13 and when examined did not seem to have any abnormalities.

In the brothers' own generation there were no other members showing similar deformities. A paternal cousin, A. D., a girl aged 16 (D-13), had had several epileptic attacks and hyperactive deep reflexes. Another paternal cousin, G. D. McG., a girl aged 15, (D-7) was born with a harelip, which was later repaired successfully. At present she still has four deciduous teeth. Examination of the other cousins on the paternal side was negative.

In the third generation, the father of our two patients, A. D., aged 53 (C-26), had ulcers on both feet beginning at the age of 16. Spicules of bone discharged through these ulcers at intervals. In most respects the ulcers behaved as in his two sons. He continued to work hard throughout all this period; at times the ulcers became infected and cellulitis of the legs developed, with a high fever. At 35 the right foot had to be amputated above the ankle joint, and soon afterward the left foot was also amputated. All told, he has had six amputations in the lower limbs within the past ten years; he has also had ulcers in several fingers from which spicules of bone would extrude spontaneously or he would extract them himself with pliers. At the present time he has no index or little finger on the right hand and a few of the fingers appear shortened, as if some of the phalanges were missing. There is complete loss of temperature sense in the hands and forearms. There is marked hypesthesia in the hands extending up and gradually disappearing toward the shoulder. There is loss of temperature and pain sense below the knee to the end of the stump, which extends about 20 cm. below the knee and is ulcerated in several areas. On roentgenologic examination there is no evidence of spina bifida. The lumbar vertebrae and bones of the pelvis are normally developed. The distal and part of the middle phalanx of the fourth finger on the right hand are absent. Some changes are beginning to appear in the distal phalanx of the first finger of the same hand. In the left hand the distal phalanges of all fingers except the first and second are absent, and a good part of the middle phalanges are destroyed (fig. 2 *E* and *F*). The patient had a brother, C. D. (C-25), who also had ulcers on both feet from early adolescence and died at the age of 31 of diabetes. In the pedigree chart he is

represented as a brother of A. D., though he was brought up as a son of A. D.'s paternal uncle. This accounts for the designation in the broken line of C-39 in figure 3. If C. D. had been a son of B-15 it would have been the only instance of the defect being transmitted through nonaffected parents. All members of the family who were interviewed were emphatic, however, in saying that C. D. was actually A. D.'s brother on his father's side, though born of a different mother. A younger brother of the father of our patients, D. D., aged 51 (C-24), has never suffered from any ulcerations; a physical examination of this man disclosed, however, definite impairment of the temperature and touch sense in a small area on the plantar and medial sides of the great toes, and hyperactive deep reflexes. All of this man's five children are in good health with the exception of one daughter, A. D. (D-13).

Of the three sisters of the father of our patients, one is apparently normal in every respect, her children and grandchildren also being normal. Of the other two, one A. D. McG., aged 42 (C-21), has hyperactive deep reflexes and small areas of loss of temperature and touch sense in the big toes. The other sister, L. D. J., aged 46 (C-22), is the only patient in the group who has all the defects. She was born with a harelip and complete cleft palate. For the past six years she has had several ulcers on the plantar surface of the left big toe and on the sole of the same foot. The ulcers are not as large as those of her nephews, but they have many of their external characteristics; they have healed and broken out several times in the past few years. Her deep reflexes are hyperactive and there is hypesthesia to touch, in some places amounting to anesthesia, with almost complete loss of temperature sense over all the toes and the plantar surface of the left foot and up to a point just below the ankle. In the right foot similar changes were noted, but over a more restricted area. She had only one child. This baby (D-8) was born with a harelip and complete cleft palate and died soon after birth.

In the second generation the only member of the family affected was T. D. Jr. (B-13), who died at the age of 42, the paternal grandfather of our two patients. According to information obtained from his wife, T. D. Jr. was the youngest in a group of nine children and the only one who had the disease. The ulcers on his feet began also in late adolescence and progressed to the point at which he had to have several toes and later both feet amputated. The man's wife states that just previous to the birth of her husband his father had contracted a venereal disease which she blamed for her husband's defect and accounted for the fact that previously born brothers and sisters had neither inherited nor transmitted the defect. T. D. Jr. had a sister, L. D. C., aged 70 (B-14), who had a baby (C-34) born with a harelip.

Of the first generation little is known. Our two patients and their grandmother had been told that our patients' great grandfather, T. A. D. (A-3), died at about the age of 80 and that just before he died gangrene of the feet developed. Up to that time, however, he had had no ulcers of the feet.

#### COMMENT

Tabes dorsalis, leprosy, syringomyelia and spina bifida occulta were considered as possibilities in the differential diagnosis. The strongly hereditary nature of the disease, the uniform date of onset, the absence of a positive history of contact and the negative sero-

logic examinations seem to exclude syphilis and leprosy from consideration. Though there are several instances of the appearance of syringomyelia in several members of one family, the fact that the disturbances first began in the lower extremities and the regularity of the age at which the onset of the disease took place seem to constitute points in favor of the hypothesis that the disturbance was due to an insufficiency or defect in the formation of the central nervous system rather than to an abnormal proliferation of neoplastic tissue in the cord. The trophic disturbances found in syringomyelia are so similar to those found in cases of spina bifida occulta that only the actual demonstration of the spina bifida can establish the diagnosis. All efforts made in that direction with our patients and their nonaffected relatives yielded, with one exception, a negative result. The exception (H. D., D-17 on the pedigree chart) did have, as shown by a roentgenogram, a spina bifida occulta; his brother, though similarly affected, did not have it. Such mild defects are, according to roentgenologists, too frequently noted in normal persons to warrant attaching much importance in this instance as being connected with the actual cause of the disease.

There are three outstanding features of this group of cases: (a) the hereditary trait, (b) the appearance of certain of the manifestations at about the same period of life and (c) the occurrence of developmental defects other than plantar ulceration in persons of the same family. One of the earliest reports of this condition is that by Bruns,<sup>2</sup> who described it as a familial symmetrical gangrene and arthropathy. The father and mother of the family he reported were over 70 years old and both healthy. There were five children, four boys and one girl. All were affected except the first born, a boy. The onset in all the affected children was at the same age, 17, with ulcers on the soles of both feet. Bruns attributed the trophic ulcers to a chronic progressive process in the lumbosacral region of the spine or in the cauda equina. One of his patients died as a result of infection but there was no autopsy.

The cases reported by Price<sup>3</sup> and Smith<sup>4</sup> are other examples of the same disturbance. Riley<sup>5</sup> reported a family in which there were several members, male and female, suffering with recurring ulcers of the feet appearing first at adolescence. In this family the mother was apparently the transmitter of this condition and more than half of her children, male and female, were affected.

Riley discusses at length the differential diagnosis between syringomyelia and myelodysplasia, a term advanced by Fuchs<sup>6</sup> to designate the clinical syndrome characterized by deformities of the feet with trophic and vasomotor disturbances, changes in the skin, spina bifida and syringomyelic sensory disturbances as well as other defects. The same condition has been described by Bremer<sup>7</sup> under the name "status dysraphicus" to indicate a disturbance in the closure

mechanism of the primitive neural tube. In the group of defects listed by Bremer are also sternal malformations, kyphoscoliosis and other developmental anomalies. The association of harelip and cleft palate with trophic defects of the feet, present in our group, has not been recorded previously so far as we know; it fits well with the conception that the underlying disturbance must be referred to an embryologic maldevelopment. As pointed out by Riley,<sup>5</sup> syringomyelia is usually marked by a slow insidious progress with involvement and destruction of the ventral horn cells adjacent to the intramedullary neoplasm, while the syndrome of myelodysplasia presents a more static state of affairs with less evidence of progress, the outstanding disturbances being associated with trophic and vasomotor control. A differentiation between the two conditions from the clinical point of view may be impossible, and a description of pathologic changes in the cord in these cases is still wanting. Though familial and hereditary features are not uncommon in syringomyelia, they are not as outstanding as in the few reported cases of myelodysplasia.

#### SUMMARY

Trophic and vasomotor disturbances with dissociated sensory changes, usually of the lower and sometimes of the upper extremities, were found in most of the male and in a few of the female members of a family some of the members of which also had harelip and cleft palate. The trophic changes first became apparent as a perforating ulcer of the feet and began at about the same age. The syndrome seems best attributed to an organized dysgenesis of the central nervous system of the type described by Fuchs under the term myelodysplasia.

## THE CLINICAL APPLICATION OF TESTOSTERONE

WALTER M. KEARNS, M.D.

MILWAUKEE

The milestones along the march of knowledge of the testicular hormone were marked in 1849 by Berthold's<sup>1</sup> injection of testicular tissue into capons, with production of the secondary male characteristic of comb growth; in 1889 by Brown-Séquard's<sup>2</sup> attempt at rejuvenating himself by injection of crude watery extracts of dog or guinea pig testes; in 1911 by Pezard's<sup>3</sup> intraperitoneal injection into capons of crushed hog testes, with the production of comb growth; in 1927 by McGee's<sup>4</sup> injection of alcoholic extract of the lipid fraction of bull testes and its detection in a five day assay on capons; from 1930 to 1938 by the development of a method for the extraction of androgens from the urine with quantitative assay on

2. Bruns, Ludwig: Familialer symmetrischer Gangrän und Arthropathie, *Neurol. Centralbl.* 22: 599, 1903. Bruns, Ludwig; Cramer, August, and Ziehen, Theodor: *Handbuch der Nervenkrankheiten im Kindesalter*, Berlin, S. Karger, 1912, p. 406.

3. Price, G. E.: Spinal Gliosis Occurring in Three Members of the Same Family, Suggesting a Familial Type, *Am. J. M. Sc.* 146: 386, 1913.

4. Smith, E. M.: Familial Neurotrophic Osseous Atrophy, *J. A. M. A.* 102: 593 (Feb. 24) 1934.

5. Riley, H. A.: Syringomyelia or Myelodysplasia, *J. Nerv. & Ment. Dis.* 72: 1 (July) 1930.

6. Fuchs, Alfred: Ueber den klinische Nachweis kongenitaler Defektbildungen in den unteren Rückenmarksabschnitten ("Myelodysplasia"), *Wien. med. Wchnschr.* 59: 2142 and 2262, 1909.

7. Bremer, F. W.: Klinische Untersuchungen zur Aetiologie der Syringomyelie der "Status dysraphicus," *Deutsche Ztschr. f. Nervenheilk.* 95: 1, 1926.

From the departments of urology and biochemistry, Marquette University School of Medicine.

Read before the annual meeting of the State Medical Society of Wisconsin, Sept. 15, 1938, at Milwaukee.

The testosterone propionate for this study (oretone and orotone ointment) was supplied by the Schering Corporation.

1. Berthold, A. A.: Transplantation der Hoden, *Arch. f. Anat., Physiol. u. Wissensch. Med.* 1849, p. 42.

2. Brown-Séquard, C. E.: Expérience démontrant la puissance dynamogénique chez l'homme d'un liquide extrait des testicules d'animaux, *Arch. de physiol. norm. et path.* 21: 651, 740, 1889.

3. Pezard, A.: Sur la détermination de caractères sexuels secondaires chez les gallinacées, *Compt. rend. Acad. d. sc.* 153: 1027, 1911.

4. McGee, L. C.: Biological Activity of Testicular Extracts, Ph.D. Dissertation, University of Chicago, 1927. The Effect of the Injection of a Lipoid Fraction of Bull's Testicle in Capons, *Proc. Inst. Med. Chicago* 6: 42, 1937.